

CASE REPORT

Recai Alemdar¹
Yusuf Aslantaş¹
Onur Çağlar¹
Ahmet Çeler²
İsmail Ekinözü¹
Hakan Özhan¹

¹Duzce University Medical
School, Department of
Cardiology, Duzce

²Duzce University Medical
School, Department of Family
Medicine, Düzce

Corresponding Address:

Doç. Dr. Hakan Özhan
Duzce University Medical School,
Department of Cardiology, Duzce
Tel: 090-532 5582873
Email: ozhanhakan@yahoo.com

Konuralp Tıp Dergisi

e-ISSN1309-3878
konuralptipdergi@duzce.edu.tr
konuralpgeneltip@gmail.com
www.konuralptipdergi.duzce.edu.tr

An Unusual Case of Mad Honey Poisoning Presented to the Emergency Clinic with ST-Wave Elevation

ABSTRACT

An unusual type of food poisoning is commonly seen in the Black Sea coast of Turkey due to grayanotoxin containing toxic honey so called “mad honey” ingestion. In cases of toxication are commonly presented with bradycardia and rhythm disturbances. We present a case of a patient whose electrocardiogram (ECG) showed ST wave elevation on admission.

Keywords: Mad Honey, Myocardial Infarction

ST Elevasyonu ile Acile Başvuran Sıradışı bir Deli Bal Zehirlenme Olgusu

ÖZET

Ülkemizde Karadeniz bölgesinde grayanotoksin ihtiva eden deli bal tüketimine bağlı sıra dışı bir gıda zehirlenmesi sık olarak görülmektedir. Zehirlenme bradikardi ve ritim problemleri ile kendini göstermektedir. Deli bal zehirlenmesine maruz kalan ve elektrokardiyografisinde (EKG) ST elevasyonu ile acile gelen bir olgu sunulmaktadır.

Anahtar Kelimeler: Deli Bal, Miyokart Enfarktüsü

INTRODUCTION

Cardiac emergencies are common in the Black Sea coast of Turkey due to grayanotoxin containing toxic honey ingestion (1-2). Although symptoms and prognosis is benign, it can manifest ECG changes mimicking acute myocardial infarction (3-6).

CASE REPORT

A 74-year-old man was admitted to our hospital with sudden development of general weakness, dizziness and a sense of compression on his chest. The symptoms began within 3 hours of mad-honey ingestion. He had previous history of hypertension. At presentation his arterial blood pressure was 80/40 mmHg and heart rate was 45 beats/min. The ECG revealed sinus bradycardia and 1-2 mm ST elevation at anterior leads with peaked T waves mimicking acute myocardial infarction (Figure 1). After 2 mg atropine injection his blood pressure and heart rate raised to 100/60 mmHg and 60 beats per minute, respectively. The laboratory test results, including cardiac troponin I and creatine kinase-MB levels were normal. The angina symptoms, ST elevation and peaked t waves on ECG were resolved within 4 hours (Figure 2). The next day the patient was taken to the catheterization laboratory for percutaneous coronary intervention. The coronary angiogram was normal.

DISCUSSION

Mad-honey intoxication is caused by grayanotoxins. Grayanotoxins lead to cardiac toxicity because they increases sodium channel permeability and activate the vagus nerve. Mad honey is very popular in the Black Sea region because it is believed to treat gastric and cardiac

diseases and to be a sexual stimulant. Plants rich in grayanotoxin responsible for honey intoxication are found in several regions of the world including Turkey, Japan, Nepal, North America and Brazil (1). Most of the cases have been reported from Turkey. Ozhan et al., reported 19 cases admitted to a hospital in Duzce, between 2002 and 2003 (2). Sutlupinar et al., reported 11 cases admitted to a hospital in Istanbul, between 1983 and 1988 (3). Generally, toxic honey disease induces dizziness, weakness, excessive perspiration, nausea and vomiting shortly after the toxic honey is ingested (1-3). Other symptoms that can occur are low blood pressure or shock, bradyarrhythmia, sinus bradycardia, nodal rhythm, Wolff- Parkinson-White syndrome and complete AV block (4). Although it has potential to cause death, so far no reported case of death due to "mad honey" toxication is present. In this case, we reported a patient whose ECG mimicking hyper acute myocardial infarction with peaked t waves and 1-2 mm ST-segment elevation. These ECG findings are rare after mad honey poisoning. Akinci at al., reported a case mad honey poisoning with ST-segment elevation (5) and Yildirim et al., reported a case with ST-segment depressions (6). Mad honey ingestion may cause severe bradycardia and hypotension which may be associated with coronary hypoperfusion. Also it can cause ECG changes as in our case (5-6). In our case, ECG became normal and the symptoms were resolved dramatically after 2 mg atropine injection. In conclusion, every possibility including myocardial infarction should be taken into account in cases of mad honey toxication and the patients should be followed for at least 24 hours.

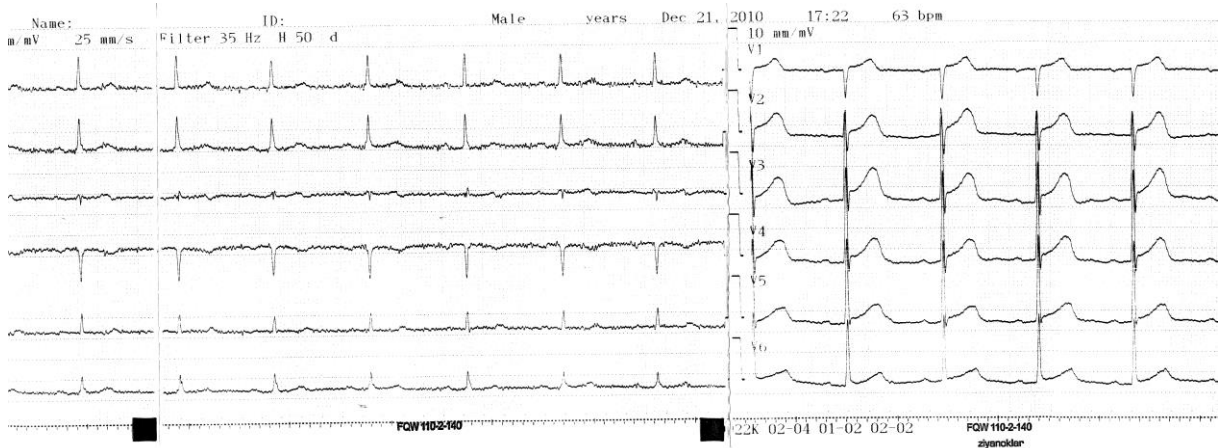


Figure 1. ECG mimicking myocardial infarction with ST wave elevation on chest leads.

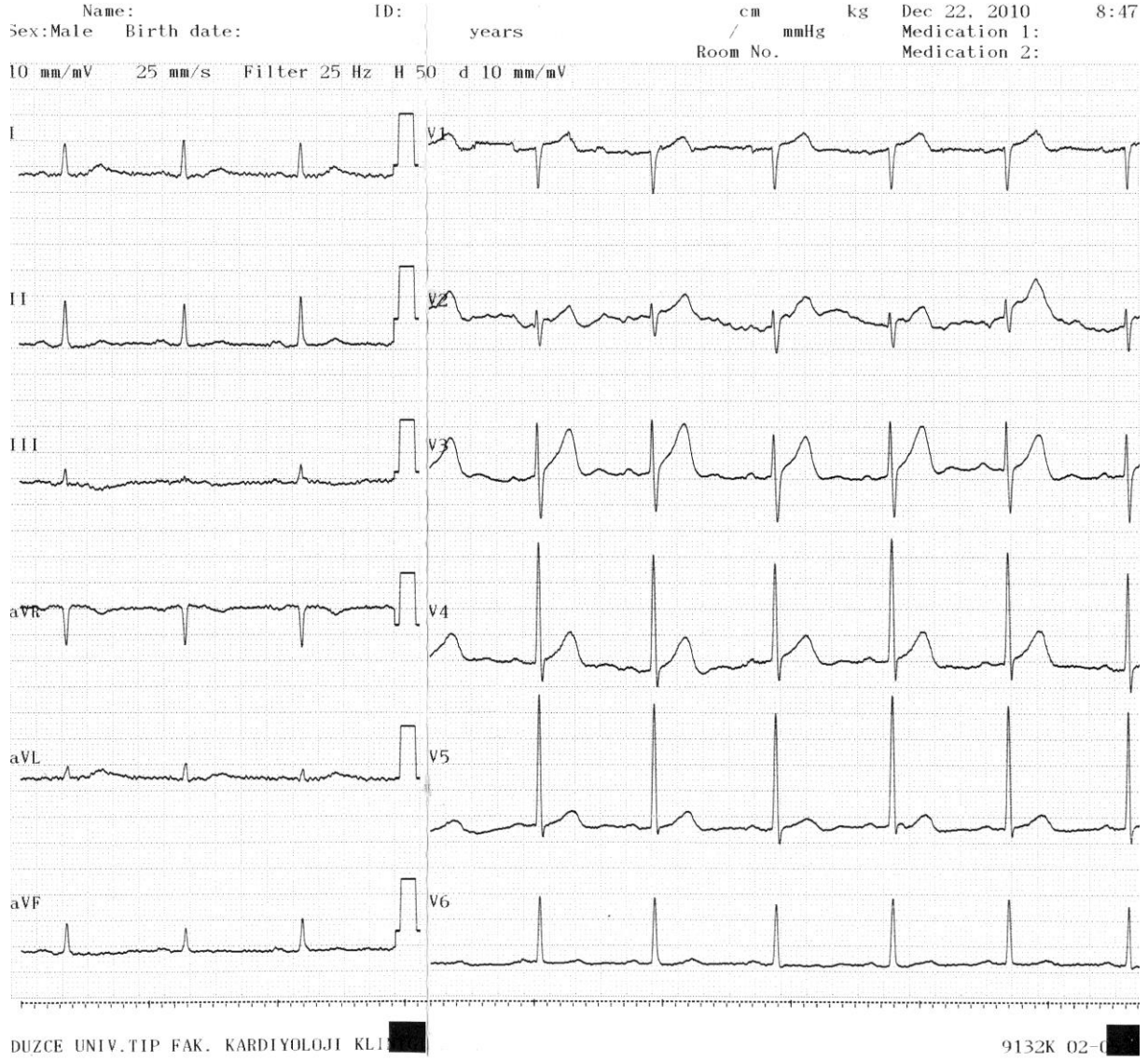


Figure 2. Moderately resolved ST elevation after therapy.

REFERENCES

1. Onat FY, Yegen BC, Lawrence R, Oktay A, Oktay S. Mad honey poisoning in man and rat. *Rev Environ Health* 1991;9(1):3-9.
2. Özhan H, Akdemir R, Yazici M, Gündüz H, Duran S, Uyan C. Cardiac emergencies caused by honey ingestion: a single centre experience. *Emerg Med J* 2004;21(6):742-4.
3. Sutlupinar N, Mat A, Satganoglu Y. Poisoning by toxic honey in Turkey. *Arch Toxicol* 1993;67(2):148-50.
4. Ergun K, Tufekcioglu O, Aras D, Korkmaz S, Pehlivan S. A rare cause of atrioventricular block: Mad honey intoxication. *Int J Cardiol* 2005; 99(2): 347-8.
5. Akıncı S, Arslan U, Karakurt K, Çengel A. An unusual presentation of mad honey poisoning: Acute myocardial infarction. *International Journal of Cardiology* 2008;129(2): e56-e58.
6. Yildirim N, Aydın M, Cam F, Celik O. Clinical presentation of non-ST-segment elevation myocardial infarction in the course of intoxication with mad honey. *American Journal of Emergency Medicine* 2008;26(1):108.e1-108.e2.